

## The Use of Frozen-thawed Spermatozoa Obtained from Alloplastic Spermatocele for Intracytoplasmic Sperm Injection

Takeshi. KURAMOTO, Arief. BOEDIONO, Michiyo. SUGIOKA,  
Tsunu. UMEBAYASHI, Kimiko. FUKUDA, Mutsuro. MOTOISHI,  
Kiyoshi. KOMATSU<sup>1)</sup>, Hirofumi. TAKIHARA<sup>2)</sup> and Hidekazu. SAITO<sup>3)</sup>

Kuramoto Women's Clinic  
Fukuoka 812-0012, Japan

<sup>1)</sup>Department of Urology, Hara Sanshin Hospital  
Fukuoka 812-0033, Japan

<sup>2)</sup>Department of Urology, Onoda City Hospital  
Onoda 756-0088, Japan

<sup>3)</sup>Department of Obstetrics and Gynecology, Yamagata University School of Medicine,  
Yamagata 990-9585, Japan

---

**Abstract:** This present study investigated the effectiveness of intracytoplasmic sperm injection (ICSI) using cryopreserved spermatozoa aspirated from alloplastic spermatocele for the treatment of 2 couples that were infertile due to obstructive azoospermia (case 1) and the emissional disorder (case 2). In case 1, the azoospermic condition was caused by previous inguinal herniorrhaphy and in case 2, the emissional disorder was caused by previous retroperitoneal lymphnode dissection for the treatment of testicular tumors. The rates of fertilization and cleavage were 100% and 100%, respectively for case 1 and 42% and 21% for case 2, after ICSI with frozen-thawed alloplastic spermatocele spermatozoa. Healthy babies were born from both wives. This clinical investigation indicates that ICSI with frozen-thawed alloplastic spermatocele sperm is an alternative treatment for infertile couples with obstructive azoospermia or emissional disorder as male factors.

**Key words:** alloplastic spermatocele, sperm cryopreservation, ICSI, male factor infertility.

(Jpn J Fertil Steril 45:233-237 2000)

---

### Introduction

A significant number of infertile men demonstrate conditions that prevent transport of spermatozoa from the somniferous tubules to the ejaculate, including congenital absence, atresia or dysplasia of the vas deferens, failed attempts at reconstruction of the vas deferens or epididymovasostomy, or ejaculation owing to retroperitoneal surgical dissection. Pamerol and Marina<sup>1)</sup> reported that 48 percent of cases of azoosper-

mia were caused by congenital anomalies of the genital tract. If both the congenital absence of ejaculatory ducts and/or an extensive segment of the vas deferentia and the acquired damages that make a reconstructive operation of the seminal pathway impossible are considered, there is a large number of patients in whom the possibility of recovering fecundity involves only the creation of a spermatocele for the retention of spermatozoa followed by intrauterine insemination (IUI). Hanley<sup>2)</sup> first created a spermatocele by mak-

ing a cavity with amniotic tissue and, subsequently achieved a pregnancy after IUI. Most reports regarding alloplastic spermatocele (AS) followed by IUI in humans, however, have indicated low success rates. Recently, intracytoplasmic sperm injection (ICSI) is the newest and most successful micromanipulation technique for treating male factor infertility<sup>3)</sup>. The subsequent fertilization of human oocytes by ICSI confirmed its clinical application for the treatment of infertile couples in whom the male partner had severely compromised semen parameters. But some patients who have male factor infertility desire their baby without attempting ICSI. They want to try IUI in their first therapy.

We reported here, the success of using cryopreserved spermatozoa obtained by AS for ICSI in 2 infertile couples whose motile sperm concentration was not insufficient for IUI.

#### Case report

Both husbands had only a single testis since they previously underwent orchiectomy in 1 testis due to testicular trauma at 37 years of age in case 1 and testicular tumors at 39 years of age in case 2. Both their wives, 37 years of age in case 1 and 39 years of age in case 2, had normal reproductive cycles. In case 1, the azoospermic condition was caused by previous bilateral inguinal herniorrhaphy and in case 2, the emissional disorder was caused by previous retroperitoneal lymphnode dissection for the treatment of testicular tumors. Testicular biopsies confirmed normal spermatogenesis and motile spermatozoa in both husbands. Therefore, the construction of alloplastic spermatocele for IUI was performed.

AS was constructed in a closed tube fashion with the use of an 8 mm diameter expanded polytetrafluoroethylen (PTFE) graft. The 5 cm graft was sutured to the ends of the bilateral side with 6-0 nylon (Fig. 1). After surgical exploration of the right testis, the vas deferens was dissected and cut while keeping the blood supply at the distant side of the testis. Then, the vas deferens was microsurgically sutured to the side point of the AS with 8-0 nylon. The AS was then placed into the scrotal space with the testis and fixed under the lateral scrotal skin to allow easy access for fluid extraction. The AS was reconstructed twice in case 1 and once in case 2 due to insufficient motile sperm concentration. Percutaneous aspiration was performed until successful sperm extraction (Fig. 2). In case 1, sperm extraction was performed 36 times and in 6 trials, motile spermatozoa were present in the extraction (Table 1). In case 2, sperm extraction was performed 7 times and in 6 trials motile spermatozoa were present (Table 1). However in both cases, IUI was not performed due to insufficient motile sperm concentration and they were attempted ICSI procedure by using cryopreserved spermatozoa Table 2 shows the concentration of spermatozoa obtained from alloplastic spermatocele just after collection, after 80% Percoll treatment and after thawing. Although cryopreservation reduced sperm quality, there were still enough aggressively motile spermatozoa for ICSI.

Wives were down-regulated with gonadotropin-releasing hormone (GnRH) analogue (Sprecur; Hoechst Marion Roussel, Tokyo, Japan) and ovarian superovulation was performed by administering human menopausal gonadotropin (hMG, Humegon; Organon, Holland) and pure follicle-stimulating hormone

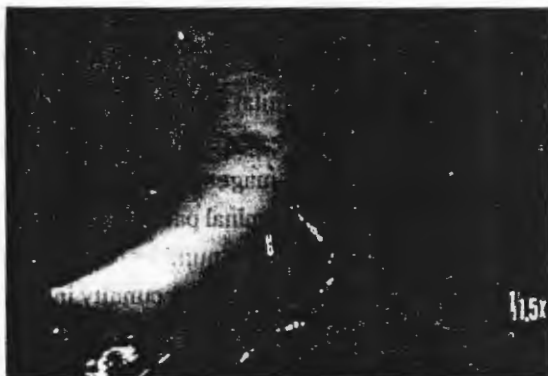

Fig. 1 Alloplastic spermatocele construction




Fig. 2 Sperm extraction from alloplastic spermatocele

Table 1. Results of spermatocele aspirations in 2 patients who had successful sperm extraction.

Grafting	Weeks after grafting	Case 1		Case 2	
		Sperm concentration*	Motility (%)	Sperm concentration*	Motility (%)
I	2	250	0	22	5
	3	420	0	21	3
	4	250	0	27	4
	5	146	0	—	—
	6	95	0	24	0
II	2	750	0	212	42
	3	—	—	110**	5
	4	166	5	64	9
	5	111	0.6	—	—
III	2	520	0	—	—
	3	231	3	—	—
	4	118	1	—	—
	5	38	3	—	—
	6	45**	9	—	—

\*Sperm  $\times 10^6/ml$ 

\*\* Initial aspiration used for ICSI

Table 2. Concentration of spermatozoa obtained from alloplastic spermatocele after collection, Percoll treatment and thawing (before ICSI was performed).

	Treatment	Sperm concentration*	Motile sperm concentration*	Motility (%)
Case 1	Aspirated sperm	45.0	4.1	9.0
	80% Percoll	68.0	10.0	15.0
	Thawing	18.0	0.8	1.0
Case 2	Aspirated sperm	110.0	5.5	5.0
	80% Percoll	193.5	52.0	27.0
	Thawing	65.5	0.8	1.0

\*Sperm  $\times 10^6/ml$ 

Table 3. Results after ICSI with frozen-thawed spermatozoa obtained from alloplastic spermatocele.

	Case 1	Case 2
No. of aspirated oocytes	7	21
No. of metaphase II oocytes injected	4	19
Intact oocytes (% of injected)	4 (100)	19 (100)
1 PN oocytes (% of injected)	0 (0)	1 (5)
2 PN oocytes (% of injected)	4 (100)	8 (42)
3 PN oocytes (% of injected)	0 (0)	1 (5)
Embryo cleaved (% of 2PN oocytes)	4 (100)	8 (100)
Transferable embryo	3	7
No. embryo transferred	3	3
No. embryo frozen	0	4

(FSH, Fertinorm P; Serono, Tokyo, Japan). Oocytes were collected with an 18 gauge single lumen needle (Hakko, Tokyo, Japan) guided by vaginal ultrasound 35 to 36 hours after hCG was administered. ICSI was performed with intact oocytes that had developed to the metaphase II stage which were identified by the presence of a single polar body. The rates of normal fertilization (with the presence of 2 pronuclei) after ICSI in cases 1 and 2 were 100% and 42%, respectively (Table 3). All fertilized oocytes cleaved and the best 3 were transferred to the mother 2 days after oocyte retrieval. Supernumerary embryos in the second couple were cryopreserved for the further use. Healthy babies were born with normal deliveries from both wives; a girl (3288g) was born to the first couple at 41 gestational weeks and a girl (3164g) was born to the second couple at 38 gestational weeks.

### Conclusion

Over the last decade, a number of investigators have used a range of spermatocele designs constructed with saphenous silicon prosthesis<sup>4)</sup>, cup-shaped silicon-dacron prosthesis<sup>5)</sup>, woven polypropylene<sup>6)</sup>, and polytetrafluoroethylen (PTFE) vascular<sup>7,8)</sup>. Although several pregnancy have been reported insemination with the spermatozoa from the alloplastic spermatocele, the results were poor. These poor results may have been due to both the low number of spermatozoa and the low number of aggressively motile spermatozoa obtained from the alloplastic spermatocele. Poor sperm recovery may have resulted from occlusion of the epididymal ducts or vas deferens, occlusion of the spermatocele lumen, and/or low sperm output by the testis. Moreover, in cases in which all of the spermatozoa were immotile, IUI resulted in no pregnancies<sup>9)</sup>. In this study, we obtained spermatozoa from the alloplastic spermatocele with expanded PTFE graft material (Fig. 1). Marmar et al.<sup>8)</sup> demonstrated that the PTFE graft prevented spermatozoa leakage and was able to withstand multiple needle punctures. Implanting the device into a dartos punch allowed easy access for aspiration. We have not encountered any problems with infections due to the grafts and to date we have not had to remove any implant. Therefore, spermatozoa collection from the alloplastic spermatocele is useful for ICSI and infertile couples who tried to IUI for their first therapy with obstructive azoospermia or ejaculatory dysfunction as male factors have more chances for ICSI.

Cryopreservation of human spermatozoa is a widely accepted technique in artificial insemination. How-

ever, it is well known that cryopreservation reduces sperm quality. Since the minimal spermatozoa require for obtaining fertilization and pregnancy after ICSI, cryopreserving poor-quality spermatozoa to perform ICSI after thawing is possible. This strategy is of great importance when we deal with valuable sperm samples, such as spermatozoa surgically retrieved from the epididymis, testicle or alloplastic spermatocele.

### References

- 1) Pamerol JM and Marina S (1976) Congenital and postinflammatory obstruction of the male reproductive tract. In: Human semen and fertility regulation in men. Hafez ESE(Ed.). St Louis: CV Mosby Co. 398
- 2) Hanley H (1955) The surgery of male subfertility; Hunterian lecture. *Ann Roy Coll Surg Eng* 17:159
- 3) Palermo GD, Joris H, Devroy P, et al. (1992) Pregnancies after intracytoplasmic injection of single spermatozoon into an oocyte. *Lancet* 340:17-18
- 4) Kelami A, Rohloff D, Affeld K, et al. (1977) Alloplastic spermatocele, insemination from epididymis reservoir. *Urology* 10:317-319
- 5) Wagenknecht LV, Weitze KH, Hoppe LP, et al. (1980) New development in surgical andrology: alloplastic spermatocele. *Invest Urol* 17:432-434
- 6) Jimenez-Cruz JF (1980) Alloplastic spermatocele. *J Urol* 123:885-886
- 7) Turner T (1988) On the development and use of alloplastic spermatoceles. *Fertil Steril* 49:387-395
- 8) Marmar JI, DeBenedictis TJ and Praiss DE (1984) Clinical experience with an alloplastic spermatocele. *J Androl* 5:304-311

(Received February 24, 2000)

(Accepted May 16, 2000)