

Morphological Characteristics of *in vitro* Cultured Cells Derived from Tumor in Domestic Animals

BAMBANG PONTJO PRISOERYANTO^{1*}, HERNOMOADI HUMINTO¹, I WAYAN TEGUH WIBAWAN¹,
RISA TIURIA¹, SUSUMU TATEYAMA²

¹Faculty of Veterinary Medicine, Bogor Agricultural University, Kampus Darmaga, Bogor 16680

²Department of Veterinary Pathology, Faculty of Agriculture, Miyazaki University, Miyazaki, Japan

Diterima 19 November 2001/Disetujui 5 Februari 2002

Twenty-two tumors derived from dog, cat, sheep, chicken, Guinea pig and cow were processed for cell culture. Cultured cells derived from mammary gland tumors could be grouped into three types; spindle, large elongated and polygonal shaped cells. The polygonal cells formed pavement-like colonies and blister-like structure or domes. The cultured cell from mixed tumor and adenoma complex showed various cell morphologies, while the cells derived from adenoma and adenocarcinoma revealed a monotonous appearance. Mesothelioma-derived cultured cells were seen as an attached cell with large and long cytoplasmic processes and the other was small to medium floating cells. The cultured cells from canine transmissible venereal tumor (CTVT) shown as floating and attached cells and cells from melanoma were elongated to spindle and round to oval shape cells with dark cytoplasmic granules. The cells derived from liposarcoma showed numerous cytoplasmic vacuoles, while the pattern of cells in monolayer derived from basal cell tumors, which could be grouped into three types revealed similarity with the histological appearance of the paraffin section. All these findings indicated that the tissue culture system might useful for the precise understanding of the morphology, proliferation and differentiation of some tumors in domestic animals.

INTRODUCTION

Tumor is one of the most important disease problems to be solved in the field of medical sciences. The cause of tumor is complex; tumor risk is related to exposure to carcinogenesis agents, environmental co-carcinogens and predisposing host factors. Neoplasia in human and domestic animals exhibits various morphology causing great difficulties in routine histological diagnosis (Destexhe *et al.* 1993, Prisoeryanto *et al.* 1997, Sari *et al.* 1997).

Little is known about the nature of cellular changes that accompany tumor progression. Since studying changes in a population of tumor cell in the intact animal is difficult, cell culture technique offers a possible way out of these limitations. The problem has been to develop system in culture that is reasonable facsimiles of the changes occurring in the organism. Dynamic changes in cellular growth properties have most obvious relevance to progression. Cell line can be the most suitable tool because it is applicable to wide variety of experiments, such as proliferation, differentiation and behavior of the tumor cell as well as production of monoclonal antibodies specific to neoplasm (Tannock & Hill 1998).

Cell culture from normal, neoplastic and embryonic tissues is a valuable tool in the medical science, and its potential value in virology, biotechnology and molecular biology have been recognized (Paul 1961, Lovel-Badge 1987, Madewell & Theillen 1987, Prisoeryanto *et al.* 1995a, Tateyama *et al.* 1995). Moreover, the reproducibility and predictability of cell culture techniques may provide some advantage for the

research on tumors such as anti-tumor drugs, hormone receptors, growth factors, specific carcinogens or carcinogenic influence and morphogenesis of tumor cells (Broder 1991, Tannock & Hill 1998).

In this study, the establishment of tissue culture derived from several tumors in domestic animals was described in order to examine their growth behavior and morphology *in vitro*. The method of Hiratsuka *et al.* (1981) was applied with a slight modification described by Tateyama *et al.* (1990a) in which mammary epithelial cells were cultured using mixed mechanical and enzyme disruption. The present study should be useful for investigation on cell growth, differentiation and proliferation as well as comparative studies of tumors.

MATERIALS AND METHODS

Tumor Tissues. Tumor tissues were obtained from biopsy or necropsy materials of 14 dogs, 4 cats, one guinea pig, one sheep, one chicken and one cow. Representative parts of the tissues were processed for routine histopathology, electron microscopy and cell culture. Histopathological diagnoses of the tumors were performed based on the standard criteria according to Moulton (1990), Goldschmidt and Shoter (1992), Jones *et al.* (1997).

Cell Dissociation. Pieces of fresh tumor tissue about 1 cm³ in size were stored in Dulbecco's modified eagle's medium and ham's nutrient mixture F-12 (DME/F-12) (Sigma, St. Louis, MO., USA), containing 10% fetal calf serum (FCS), 100 IU/ml penicillin and 100 ug/ml streptomycin, for 1-2 h at 4°C for sterilization. The tissue was minced finely with scissors and resuspended in digestion medium (928 U

* Penulis untuk korespondensi, Tel. +62-251-421807, Fax. +62-251-421807, E-mail: bpontjo@indo.net.id

collagenase, Wako, Osaka, Japan) and incubated for 8-16 h in a 95% air/ 5% CO₂ atmosphere at 37°C. The cell suspension were filtered with a stainless steel mesh cloth (size 80 um) and centrifuged at 1,000 rpm for 10 min. The supernatant was discarded and the pellet was washed gently by pipetting in 5 ml of culture medium and left to stand for 10 min. The resulting supernatant was used as the S-1 fraction. The pellet was then resuspended in 5 ml of culture medium and left to stand for 10 min, after which the resulting supernatant was used as the S-2 fraction. The pellet was treated again, following the same procedure for the S-3 and S-4 fractions (Priosoeryanto *et al.* 1995bc).

Cell Culture. The dissociated cells were plated and viability was estimated by a Trypan Blue dye exclusion test. The cells were plated at a density of 1.0 x 10⁵ cells/ml in a 50-mm dish, together with 18 x 18 mm² coverslips for electron microscopic study in DME/F-12 medium supplemented with 10% FCS, 100 IU/ml penicillin and 100 ug/ml streptomycin, 20 ng/ml epidermal growth factor, 10 ug/ml insulin and 1 ug/ml hydrocortisone. The culture dishes were maintained in a 95% air/ 5% CO₂ atmosphere at 37°C and observed daily using a phase-contrast microscope (Nikon, DIAPHOT-TMD, Tokyo, Japan).

Subculture was made by washing with 0.2 mM ethylenediamine tetraacetic acid in phosphate-buffered saline (EDTA-PBS) and digestion with 0.05% trypsin in EDTA-PBS, followed by incubation in a 95% air/ 5% CO₂ atmosphere at 37°C for 7 min. Then DME/F-12 medium containing 10% FCS was added to stop the trypsinization. The viable cells were adjusted to 5.0 x 10⁵ cells/ml and plated in a 50-mm dish. The cells were stocked in medium consisting of DME/F-12 containing 10% FCS and 10% dimethylsulfoxide (DMSO) and stored at -80°C and then in liquid nitrogen and were kept until used (Freshney 1992, Priosoeryanto *et al.* 1995bc).

Collagen Gel Culture. Only cells derived from mammary tumors were cultured on the surface or within the collagen gel. Collagen gel was reconstituted according to the manufacturer's recommendations. Briefly, eight volumes of acid-soluble type I collagen solution from porcine tendon (Cellmatrix IA, 3mg/ml, pH 3.0, Nitta, Osaka, Japan) were mixed with two volumes of 5 times concentrated DME/F-12 and one volume of reconstituted buffer (2.2 g NaHCO₃ in 100 ml of 0.05 N NaOH and 200 mM N-2-hydroxyethylpiperazine-N'-2-ethanesulfonic acid/ HEPES), and kept on ice. For fixed or floating collagen gel cultures, 1.5 ml of the collagen gel solution was spread onto 35-mm dishes. After polymerization at 37°C for 15 min, the gel was overlaid with 2 ml of cell suspension. For gel-embedded cultures, the cell suspension was centrifuged at 1,000 rpm for 5 min, and 1.5 ml of collagen solution was added to the cell precipitate. The cell suspension with collagen gels was spread onto a 35-mm dish, incubated at 37°C for 15 min, and then overlaid with 2 ml of DME/F-12 supplemented with 10% fetal calf serum (FCS), and observed daily by phase-contrast microscope (Priosoeryanto *et al.* 1995c).

Light Microscopy. Coverslips with attached cells were washed in phosphate buffered saline (PBS), fixed for 30 min. in methanol Carnoy's solution and finally were stained with hematoxylin-eosin (HE) and other special staining as required (Priosoeryanto *et al.* 1995bc).

RESULTS

In general, within 24 h after plating on the plastic dishes during the primary culture, the cells began to emerge from the attached organoids or cell clumps. Passage time and culture period of tumor cells are summarized in Table 1.

Culture of Mammary Tumors. Between 3-12 days of culture, primary culture of mammary tumors from 5 dogs and one cat showed several types of cell shapes, which could be grouped generally into 3 types. The first was spindle shaped (Figure 1a), the second was large elongated spindle (Figure 1b) and the third was polygonal shaped cell forming typical growth pattern of colonies called "pavement-like appearance" (Figure 1c). Several blister-like structures or "domes" appeared in confluent culture. In the course of growth, the colonies fused each other and formed cell sheets. Some large and small spindle shape cells were observed in the space among colonies consisting of epithelial cells. In the culture from benign mixed tumors, several cell morphologies as described

Table 1. Passage times and culture periods of tumor cells

Animal	Tumor type	Passage	Culture period (day)	
			Primary*	Total**
Dog	Adenoma	6	6-12	53
Dog	Adenocarcinoma	21	4-6	149
Dog	Benign mixed tumor	86	3	Continuous growth
Dog	Adenoma complex	9	4-8	60
Dog	Malignant mixed tumor	5	5-8	35
Cat	Adenocarcinoma simple type	15	4-6	72
Dog	Mast cell tumor	3	5	22
Dog	Canine transmissible venereal tumor	2	6-18	21
Dog	Malignant mast cell tumor	3	5-7	24
Dog	Acanthomatous epulis	81	2	Continuous growth
Dog	Anaplastic carcinoma	9	5	65
Dog	Myxofibroma	3	4-7	30
Dog	Basal cell tumor	3	4-6	27
Dog	Malignant melanoma	5	3-5	30
Dog	Mesothelioma	4	4	20
Cat	Signet ring cell carcinoma	4	5	22
Cat	Amelanotic melanoma	4	3-6	21
Cat	Squamous cell carcinoma	6	7-12	Continuous growth
Chicken	Squamous cell carcinoma	3	3-5	18
Sheep	Hepatocellular carcinoma	5	4	22
Cow	Papilloma	5	4	26
Guinea pig	Liposarcoma	3	4-8	20

* Days from first plating to first passage, ** Days from first plating to end of growth

above were also seen, while the cultured cells derived from solid carcinoma showed monotonous appearance of the colonies representing round to oval cells with large nuclei and one or more prominent nucleoli (Figure 1d). The cell morphology of the cultured cells depended on the tumor type. Cultured cells derived from benign mixed tumor, adenoma complex and malignant mixed tumor showed various morphologies, whereas cells from adenoma and adenocarcinoma were more uniform. The morphologic characteristics of the cultured cells are summarized in Table 2.

The mammary tumors cells grew on the surface or fixed collagen gel were appeared as a rounded to elongated structures, while the cells on the floating collagen gel were rounded to oval. The growth pattern of cells embedded within the collagen gel was characterized by the oval to elongated three-dimensional structures and they grew actively with branching arrangement and formed duct-like structures (Figure 2).

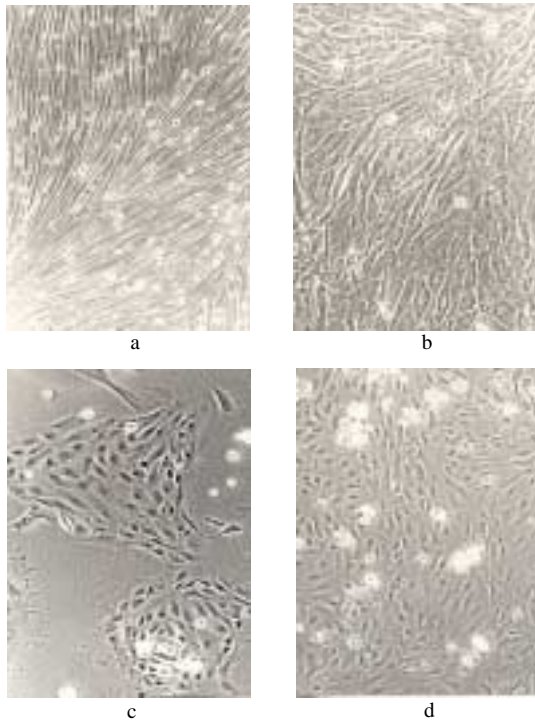


Figure 1. Phase-contrast microscopy observation of the cultured cells derived from canine mammary gland tumors. a. Spindle shape cells, b. Large elongated spindle, c. Polygonal shape cells with pavement-like colony, d. The cultured cells derived from solid carcinoma showing monotonous appearance of the colony x200.

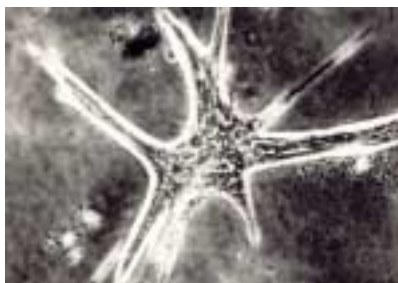

Figure 2. The cultured cell derived from mammary gland tumor embedded within the collagen gel matrix show three dimensional colonies and duct-like structure. Phase-contrast x300.

Cultured of Other Tumors. A few days after primary culture (depending on the tumor types), some cell clumps began to attach to the plastic dishes. These small colonies progressively became larger when allowed to age a few days after confluence and tended to unite forming large aggregates (Table 2).

The cultured cell derived from canine transmissible venereal tumor (CTVT) showed two cell appearances, floating and attached cells. The number of floating and attached cells increased slowly. In the second passage, some large attached cells with numerous vacuoles were encountered, and then the cultured cells stopped growing and degenerated.

In malignant melanoma, the cultured cells were elongated to spindle and round to oval shaped cells. The elongated to spindle cells were slender with round to oval vesicular nuclei and large nucleoli, while the round to oval cells had one or more nucleoli. In some cells, dark granules considered as melanin granules were encountered on their cytoplasm (Figure 3). Both types of cells were adhered weakly to the dish wall.

When allowed to age a few days after confluence was attained, the cultured cells derived from liposarcoma showed stellate to elongated shaped cells containing many vacuoles considered to be intracytoplasmic lipid droplets. These cells had round nuclei, a finely granular chromatin pattern with

Table 2. Morphology of the cultured cells

Animals	Tumor type	Cell morphology
Dog	Adenoma	Small round to oval
Dog	Adenocarcinoma	Small and large round to oval
Dog	Benign mixed tumor	Round to oval and some elongated
Dog	Adenoma complex	Round to oval with some elongated spindle
Dog	Malignant mixed tumor	Small and large round to oval
Cat	Adenocarcinoma simple type	Small round to oval
Dog	Mast cell tumor	Oval to elongated
Dog	Canine transmissible venereal tumor	Large elongated and round floating
Dog	Malignant mast cell tumor	Oval to elongated
Dog	Acanthomatous epulis	Round to oval with some marked keratinised
Dog	Anaplastic carcinoma	Small and large round to oval
Dog	Myxofibroma	Elongated to spindle
Dog	Basal cell tumor	Small and large round to oval with some spindle
Dog	Malignant melanoma	Elongated to spindle with dark cytoplasmic granules
Dog	Mesothelioma	Attached cell with large and long cytoplasmic processes and the other was small to medium floating cells
Cat	Signet ring cell carcinoma	Small and large round to oval
Cat	Amelanotic melanoma	Elongated to spindle
Cat	Squamous cell carcinoma	Round to oval with some marked keratinised
Chicken	Squamous cell carcinoma	Round to oval with some marked keratinised
Sheep	Hepatocellular carcinoma	Small and large round to oval
Cow	Papilloma	Small round to oval
Guinea pig	Liposarcoma	Oval to elongated

peripheral margination, microfilaments and one or more prominent nucleoli.

There were two types of cells derived from pleural effusion of mesothelioma, one was attached cell with large and long cytoplasmic processes and the other was small to medium floating cell (Figure 4). The number of the floating cells was dominant when they let to age; and they weakly connected with the attached cells.

In the cells derived from basal cell tumors, the typical pattern of cells in monolayer was round to oval surrounded by spindle to elongated cells (Figure 5a). Judge from the pattern of cell growth, they can be classified into 3 categories: (i) the migratory zone in the periphery of the organoids, in which the cell density was high, clearly spindle-shaped and was arranged in more or less distinct bands radiating from the organoids, (ii) single cell, which occurred throughout the cultures and showed distinct polymorphism, from spindle shape or an irregular shape to rounded or polygonal shape with distinct cell borders and no processes, and (iii) cell clumps or organoids, which varied considerably in size and density and occurred throughout the cultures. Migration of cells from the edge of some organoids was seen. The culture morphology somehow reflects the histological pattern of the original tumor tissue (Figure 5b), based on some similarity pattern among cell colonies of the tumor tissue in paraffin sections which showed epithelial cells surrounded by spindle shape cells considered as fibroblast.

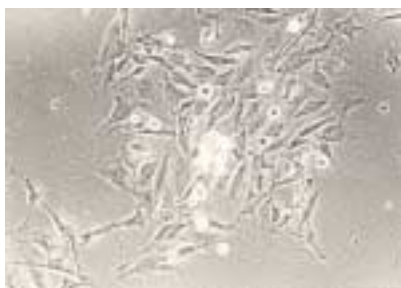

Figure 3. The cultured cells derived from malignant melanoma revealed an elongated to spindle and round to oval shape with dark granules on their cytoplasm. Phase-contrast, x200.

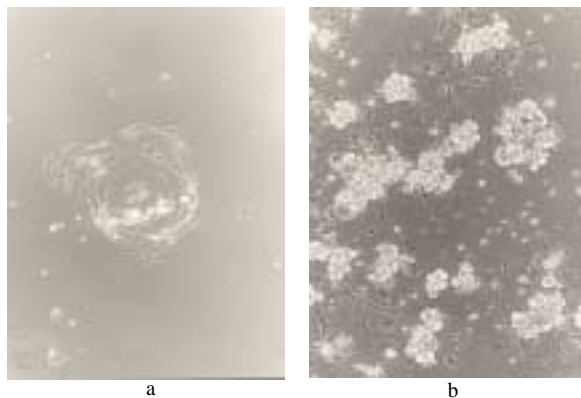


Figure 4. Morphology of the cultured cell derived from mesothelioma. a. At primary culture the cells displayed attached spindle with long cytoplasmic processes shape cells and floating cells. b. At the second passage the floating cells with small to medium in size were predominant. Phase-contrast x150.

DISCUSSION

The common features of growth pattern for cell culture derived from mammary tumors were small and large round to oval shaped cells in the center, and surrounded by elongated to spindle shaped cells. These findings were also previously reported (Tateyama *et al.* 1990b). The arrangement of this growth pattern seemed to somehow reflect the *in vivo* texture of the mammary tissue. It is well known that myoepithelial cells are situated in the basement area and the glandular epithelial cells in the organoids (Namba *et al.* 1982). The cell populations that grow from organoids may contain glandular epithelial and myoepithelial cells (McGrath & Soule 1983, Tateyama *et al.* 1990a), therefore the polygonal cells might be glandular epithelial cells, while the large elongated to spindle-shaped cells are considered as myoepithelial cells (Tateyama *et al.* 1990ab, Priosoeryanto *et al.* 1995b). Observation of fibroblast or myofibroblast is also necessary since they are also present in the canine mammary carcinoma, and plays some significant roles (Hayden *et al.* 1986, Tateyama *et al.* 1988).

The differences in appearance of the mammary gland cultured cells were depended on the tumor type, these might be due to the *in vivo* condition. In the mixed tumors type, they accompanied by other cell types originate from their parental organ (in this case alveolar epithelial and myoepithelial cells), while in malignant tumors type the cells can proliferate by themselves (Tateyama *et al.* 1990b). In a previous paper (Kawano *et al.* 1988) the pure epithelial cell obtained from milk could not proliferate when embedded in gel, due to the absence of fibroblast which is suggested to play an important role in the proliferation and differentiation of epithelial cells (Tateyama *et al.* 1990b).

There is an indication that neoplastic mammary cells also grow better in collagen gel matrix (Kano-Sueko 1983), therefore, at least certain mammary carcinomas seem to favor the collagen gel matrix for their growth (Tateyama *et al.* 1990ab, Priosoeryanto *et al.* 1995b). The collagen culture may offer advantages as substitute of *in vivo* in observing cell morphology whereas plate culture for continuous subculture (Tateyama *et al.* 1990b).

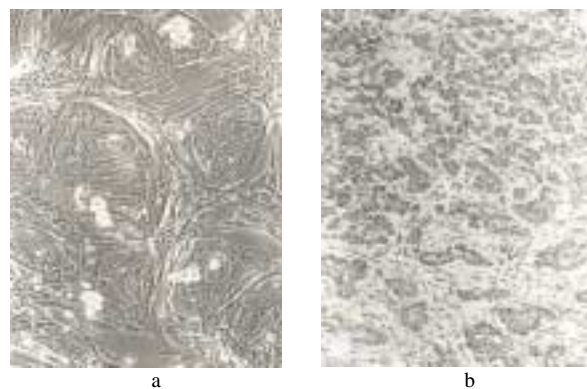


Figure 5. The confluent culture of the cultured cells from canine basal cell tumor. a. The polygonal cells were surrounded by spindle cells, phase-contrast x225; b. Paraffin section of the original tissue from canine basal cell tumor, hematoxylin-eosin x170.

The cell origin of the CTVT is not precisely known (Nielsen & Kennedy 1990). There are some arguments that CTVT is originated from several cells, such as lymphocytes, histiocytes, reticular cells and mature end cells of the reticuloendothelial series (Kaalund-Jorgensen & Thomsen 1937, Mulligan 1949, Bloom *et al.* 1951). The present tissue culture study also expressed several cell morphologies. It has been reported that when this tumor is grown in cell culture, the cell population changes from a mixture of tumor cells and a few fibroblast to a culture of pure fibroblast; the tumor cells die out more rapidly than their ability to divide, and fibroblast take over (Bloom *et al.* 1951, Yang *et al.* 1973).

Histopathologically, melanomas in domestic animals can be classified into epitheloid, spindle and mixed cell types. Our present tissue culture study of canine melanoma tumor cells expressed two types of cells. The criteria used to distinguish between spindle and epitheloid cells are largely those used for the characterization of benign and malignant melanoma cells (Diters *et al.* 1983). The appearance of the present cultured cells, suggest that the elongated to spindle cells is identical to the spindle cell classified by Pulley and Stannard (1990), while the round to oval cells are similar to that of epitheloid cells.

One major problem in the studies of the origin of primary culture of epithelial cells derived from tumor tissue has been the identification of the epithelial cells. Two approaches in addition to the use of precisely light microscopic criteria have been reported, as the demonstration of desmosomes (Russo *et al.* 1975) and specific epithelial surface antigen or intermediate filaments (Easty *et al.* 1980, Priosoeryanto *et al.* 1992). In the present study of the cultured cells derived from basal cell tumor we use both of these criteria. The cell clumps were identified as epithelial cells, while the cells in the periphery of the cell clumps and the single cells were identified as fibroblast.

Three of the cultured cells were able to keep grown and maintained for long period; two of them were developed and established as cell line, while the rest is still in process for establishing as another new cell line. The present study show that the tissue culture system maybe useful in the precise understanding of the cell morphology, proliferation and differentiation of some tumors of domestic animals.

ACKNOWLEDGEMENTS

The authors wish to thanks the Directorate General of Higher Education, Ministry of National Education for funding this research through the Competitive Grant VI (Hibah Bersaing) project 1997-2000 and also to the Department of Veterinary Pathology, Faculty of Agriculture, Miyazaki University-Japan.

REFERENCES

Bloom F, Paff GH, Noback CR. 1951. The transmissible venereal tumor of the dog: Studies indicating that the tumor cells are mature end cells of reticuloendothelial origin. *Amer J Path* 27:119-140.

Broder S. 1991. *Molecular Foundations of Oncology*. Baltimore: William & Wilkins.

Destexhe E, Lespagnard L, Degeyter M, Heymann R, Coignoul F. 1993. Immunohistochemical identification of myoepithelial, epithelial, and connective tissue cells in canine mammary tumors. *Vet Pathol* 30:146-154.

Diters RW, Dubielzig RR, Aguirre GD, Acland GM. 1983. Primary ocular melanoma in dogs. *Vet Pathol* 20:379-395.

Easty GC, Easty DM, Monaghan P, Ormerod MG, Neuville AM. 1980. Preparation and identification of human breast epithelial cells in culture. *Int J Cancer* 26:577-584.

Freshney RI. 1992. *Animal Cell Culture A Practical Approach*. Ed ke-2. Oxford: IRL Pr.

Goldschmidt MH, Shoter FS. 1992. *Skin Tumors of the Dog and Cat*. Oxford: Pergamon Pr.

Hayden DW, Ghorial HK, Johnson KH, Buoen LC. 1986. Feline mammary sarcoma composed of cells resembling myofibroblast. *Vet Pathol* 23:118-124.

Hiratsuka M, Senoo T, Kimoto T, Namba M. 1981. [Cultivation of human mammary epithelial cells] [dalam bahasa Jepang]. *Soshikobaiyou* 7:431-437.

Jones TC, Hunt RD, King NW. 1997. *Veterinary Pathology*. Ed ke-6. Baltimore: William & Wilkins.

Kaalund-Jorgensen O, Thomsen AS. 1937. Det overfor bare veneriske sarkom hos hunde. *Maanedsskr. Dyrlaeger* 48:561-578.

Kano-Sueko T. 1983. Factors affecting mammary cells in culture. *Biochemical Actions of Hormones*. Vol X. Academic Pr, Inc. hlm 163-185.

Kawano A, Tateyama S, Yamaguchi R, Nosaka D, Kondo F. 1988. Morphology of goat milk-derived mammary epithelial cells cultured in collagen gel. *Jpn J Vet Sci* 50:1252-1258.

Lovell-Badge RH. 1987. Introduction of DNA into embryonic stem cells. Di dalam: Robertson EJ (ed). *Teratocarcinomas and Embryonic Stem Cells*. A practical approach. Oxford: IRL Pr. hlm 153-182.

Madewell BR, Theillen GH. 1987. Tumors of the mammary gland. Di dalam: Theillen GH, Madewell BR (ed). *Veterinary Cancer Medicine*. Ed ke-2. Philadelphia: Lea and Febiger. hlm 372-344.

McGrath CM, Soule HD. 1983. Renewal inhibition of human mammary cell growth *in vitro*: Cortisol and the recruitment of cells to terminal differentiation. *J Cell Physiol* 116:385-396.

Moulton JE. 1990. *Tumors in Domestic Animals*. Ed ke-3. Berkeley: University of California Pr.

Mulligan RM. 1949. *Neoplasma of the Dog*. Baltimore. William & Wilkins.

Namba M, Hyodo F, Hiratsuka M, Senoo T, Kimoto T. 1982. [Ultrastructure of cultured human mammary cells] [dalam bahasa Jepang]. *Saibou* 14:62-67.

Nielsen SW, Kennedy PC. 1990. Tumors of the genital system. Di dalam: Moulton JE (ed). *Tumors in Domestic Animals*. Ed ke 3. Berkeley: University of California Pr. hlm 479-517.

Paul J. 1961. *Cell and Tissue Culture*. Ed ke-2. Edinburgh: E & S Livingstone Ltd.

Priosoeryanto BP, Huminto H, Wibawan IWT, Bahagia S, Estuningsih S, Harlina E, Ratih D, Tateyama S, Yamaguchi R, Uchida K. 1997. In vitro and ultrastructural studies of canine tumors. Di dalam: *Proceeding of the first ASEAN Microscopy Conference*. Johor-Bahru, Malaysia, 27-30 Nov 1997. hlm 57-59.

Priosoeryanto BP, Tateyama S, Yamaguchi R, Uchida K. 1995a. Antiproliferation and colony-forming inhibition activities of recombinant feline interferon (rFeIFN) on various cells *in vitro*. *Canadian J Vet Res* 59:67-69.

Priosoeryanto BP, Tateyama S, Yamaguchi R, Uchida K. 1995b. Establishment of a cell line (MCM-B2) derived from a benign mixed tumor of canine mammary gland. *Res Vet Sci* 58:272-276.

Priosoeryanto BP, Tateyama S, Yamaguchi R, Uchida K, Ogawa H, Nakai M. 1995c. A cell line (MCA-B1) derived from a canine oral acanthomatous epulis. *Res Vet Sci* 58:101-103.

Priosoeryanto BP, Yamaguchi R, Tateyama S, Matsuyama K. 1992. Microscopical and immunohistochemical studies on intestinal signet ring-cell and pulmonary bronchiolar-alveolar carcinoma in a cat. *Hemera Zoa, Indonesian J Vet Sci* 75:57-69.

- Pulley LT, Stannard AA. 1990. Tumor of the skin and soft tissue. Di dalam: Moulton JE (ed). *Tumors in Domestic Animals*. Ed ke-3. Berkeley: University of California Pr. hlm 23-87.
- Russo J, Furmanski P, Rich MA. 1975. An ultrastructural study of normal human mammary epithelial cells in culture. *Am J Anat* 142:221-231.
- Sari DK, Priosoeryanto BP, Yamaguchi R, Ratih D, Tateyama S, Uchida K. 1997. Ultrastructural and pathological studies of transplantable canine lung carcinoma cell in Severe Combined Immunodeficiency (SCID) mice. Di dalam: *Proceeding of the first ASEAN Microscopy Conference*. Johor-Bahru, Malaysia, 27-30 Nov 1997. hlm 62-63.
- Tannock IF, Hill RP. 1998. *The Basic Science of Oncology*. Ed Ke-3. Singapore: McGraw-Hill International. Health Profession Division.
- Tateyama S, Furukawa H, Yamaguchi R, Nosaka D, Kondo F. 1990a. Plate and collagen-gel cultures of normal canine mammary epithelial cells. *Res Vet Sci* 49:14-19.
- Tateyama S, Furukawa H, Yamaguchi R, Nosaka D, Otsuka H, Sasaki N. 1990b. Plate and collagen gel culture of neoplastic canine mammary epithelial cells. Di dalam: *Proceeding of the 7th Congress of Federation of Asian Veterinary Association (FAVA)*. Pataya, Thailand. hlm 622-634.
- Tateyama S, Priosoeryanto BP, Yamaguchi R, Uchida K, Ogiwara K, Tsuchiya A. 1995. *In vitro* growth inhibition activities of recombinant feline interferon on all lines derived from canine tumours. *Res Vet Sci* 59:275-277.
- Tateyama S, Shibata I, Yamaguchi R, Nosaka D, Ashizawa H. 1988. Participation of myofibroblast in feline mammary carcinoma. *Jpn J Vet Sci* 50:1048-1054.
- Yang TJ, Wang NS, Jones JB. 1973. A study of the cytology and cell culture of the canine transmissible venereal sarcoma. *Experientia* 29:1133-1134.