

Apoptotic Cells in Dominant Follicles in Japanese Black Cows

AMROZI¹⁾, Shunichi KAMIMURA²⁾, Takaaki ANDO and Katsumi HAMANA
(Laboratory of Theriogenology)

Received for Publication, September 10, 2004

Summary

Ovarian dynamics in six Japanese Black cows with two and three follicular waves (FWs) were determined by means of ultrasonography twice daily and blood was sampled for progesterone analysis. Ovariectomy was performed at Day 18 a.m. (Day 0 = estrus) to evaluate the apoptotic cells in the preovulatory dominant follicle (DF) by TUNEL method. Three cows showed 2 follicular waves (FWs) in the estrous cycle, where emergence of FW 1 and 2 were observed on Day 1.3 ± 0.3 and 10.2 ± 0.3 , respectively. Maximum diameter of the DF in FW 1 was 12.2 ± 0.8 mm on Day 7 p.m. and 11.7 ± 0.8 mm on the day of ovariectomy in FW 2. The other three cows have 3 FWs where FW 1, 2 and 3 emerged on Day 1.2 ± 0.3 , 8.8 ± 0.3 and 14.8 ± 1.3 , respectively. The DF of FW 1, 2 and 3 increased its diameter until Day 7 a.m. (12.6 ± 0.8 mm) and Day 15 p.m. (11.2 ± 1.3 mm), and the day of ovariectomy (9.4 ± 3.0 mm), respectively. The prevalence of apoptotic cells in GCs and TCs in the preovulatory DF was $6.7 \pm 2.3\%$, $2.8 \pm 0.6\%$ in cows with 2 FWs and $10.5 \pm 2.5\%$, $5.8 \pm 3.0\%$ in cows with 3 FWs, respectively. The prevalence of apoptotic cells was significantly higher for GCs than TCs in all groups ($P < 0.05$). In conclusion, the results showed that apoptotic cells occurred in preovulatory DF on Day 18 of the estrous cycle and the prevalence of apoptotic cells was higher in GCs than in TCs.

Key words: apoptosis, Japanese Black cows, ovariectomy, preovulatory dominant follicle, ultrasonography

Introduction

Two or three follicular waves (FWs) are present during the bovine estrous cycle, the emergence of the 3rd wave is associated with a longer luteal phase, and the viable dominant follicle (DF) present at the time of luteolysis becomes the ovulatory follicle [10]. In the first FW, the DF and its cohort become atretic and are followed by the development of the second and/or preovulatory FW.

Apoptosis is a process of selective cell deletion by means of underlying ovarian follicular atresia [2, 12, 15, 30]. This process occurs either in healthy, early atresia or atretic follicles with morphological characteristics of apoptotic cells in nuclei with marginated chromatin, a single condensed

¹⁾ Present address: Department of Reproduction and Obstetrics, Faculty of Veterinary Medicine, Bogor Agricultural University, Kampus IPB Darmaga, Bogor 16680, Indonesia.

²⁾ CORRESPONDENCE TO: KAMIMURA, S., Laboratory of Theriogenology, Kagoshima University, Korimoto 1-21-24, Kagoshima 890-0065, Japan.
Tel/Fax: +81-99-285-8737, Email: kamimura@agri.kagoshima-u.ac.jp

nucleus, multiple nuclear fragments or membrane bound structures containing variable amounts of chromatin (apoptotic bodies) [2, 3, 14, 30].

The preovulatory DF is under the control of static and regressing P_4 levels with increasing estrogen levels and intensive LH pulse compared to the first wave anovulatory DF. Luteinizing hormone and hCG are capable of maintaining granulosa cells from apoptosis [7, 24, 27]. As to the apoptosis in the preovulatory DF in goats, there is a progressive increase in apoptotic cells within the ovarian surface epithelium, tunica albugenea and apical follicular wall [17]. Moreover, apoptosis and necrosis contribute progressively to the follicular stigma formation and ovarian rupture in ewes [18]. The objective of the present study was to determine whether apoptosis in the preovulatory DF which had emerged on different days in cows with 2 and 3 FWs show a similar pattern to the first wave atretic DF in which the older follicles have higher apoptotic cells.

Materials and Methods

Animals, Experimental Design, Ultrasonography and Ovariectomy

Six Japanese Black cows were subjected to ovariectomy on Day 18 a.m. of the estrous cycle (Day 0 = estrus) to obtain the DF. They were in healthy BCS (2.5-4.0 of 5 scores) and had calved 8.7 ± 1.8 times. In the experiment, animals were divided respectively into the following 2 groups: cows with 2 FWs in an estrous cycle and cows with 3 FWs in an estrous cycle retrospectively. All animals were kept in a stanchion barn at the Animal Hospital, Kagoshima University.

In order to induce ovulation, $PGF_{2\alpha}$ (Pronalgon[®]F, Pfizer, Japan) was injected intramuscularly twice a day at 07:00 (15 mg) and 19:00 (10 mg) during the mid luteal phase. Dynamics of the DF, SF and CL in the ovaries were monitored twice daily at 07:00 and 19:00 with ultrasonography before and after the treatment with $PGF_{2\alpha}$ until ovariectomy (Day 18 a.m.) by the same operator to maintain the similar evaluating conditions. A real time B-mode ultrasound scanner (EUB-405, Hitachi-Medical Co., Tokyo) equipped with a 7.5 MHz transducer (EUP-033J, Hitachi-Medical Co., Tokyo) was used. Sequential identification of individual follicles more than 2 mm in diameter was carried out. Appropriate images of follicles were arrested on screen and maximum diameters of follicles were measured using a built in caliper system. The images of follicles were hard-printed. Ultrasonic images of the ovaries were recorded on the follicular map. The day when the dominant follicle was clearly identified (4 mm) for the first time by means of ultrasonography was retrospectively defined as the day of FW emergence [11]. The first FW that emerged after ovulation was defined as FW 1. Ovariectomy was performed by the flank laparotomy under epidural anesthesia at 07:00 on Day 18 a.m. of the estrous cycle to collect the ovaries.

Processing of Ovaries

Following ovariectomy, ovaries were immediately placed in physiological saline. Thereafter, ultrasonographic detections were carried out to confirm the relative location of the DF, which had been identified by the previous ultrasonographic examinations before ovariectomy. After confirmation, the DF was dissected free from the extraneous tissue under the stereomicroscope. An individually dissected follicle was placed in the glass jar and was opened to collect the follicular wall. Follicular walls were immediately put into 10% phosphate-buffered formalin. Follicular tissues were processed for histology, and embedded in the paraffin wax.

Detection of Apoptosis by TUNEL (Terminal Deoxynucleotidyl Transferase-Mediated dUTP

Nick-End Labeling): Light Microscopy

Follicular walls were sectioned at 5 μm and were mounted on 3-aminopropyltri-ethoxy-silane coated slides (DakoCytomation, Kyoto, Japan) dried in 40°C for 12 hr, dewaxed, and hydrated. Briefly, the DNA 3'-end labeling was performed in a humidified chamber for 60 min at 37°C in enzyme solution, terminal deoxynucleotidyl (TdT) transferase (*In Situ* Cell Death Detection Kit, POD, Roche, Indianapolis, IN, USA) following the previous analysis method [2]. Normal calf ovary sections were used for the negative and positive controls of immunohistology staining. Negative control slides were incubated in label solution without terminal transferase.

The number of TUNEL-labeled cells in GC and TC layers was counted at 10 fields per follicle under a light microscope (Nikon Eclipse E800, Tokyo, Japan) equipped with a digital camera (Nikon Digital Camera DXM1200, Tokyo, Japan) at x40 objective. Cells considered TUNEL-positive when brown staining, combined with the characteristic apoptotic appearance (marginated chromatin, pyknosis or multiple fragmentations) were counted. Less staining cells were expelled from analysis. Apoptotic bodies that occurred in clusters adjacent to one another were counted as a single event.

Blood Plasma Sampling and Hormone Determinations

Blood from the jugular vein was collected daily before PGF_{2 α} treatment and twice daily following PGF_{2 α} treatment at the same time as ultrasonography. Plasma was collected by centrifugation of the blood samples at 4°C, 1670 g for 20 min and then plasma samples were stored at -20°C. Double antibody RIA was used to determine the concentrations of progesterone using antisera to progesterone (GDN # 337) [28]. The intra and interassay coefficients for progesterone were 4.2 and 8.0%, respectively.

Data Analysis

The number of animals observed until Day 18 a.m. was six. Values were expressed as mean \pm SD. Mean values in BCS, calving numbers, day of follicles emergence, follicle diameter, hormone levels and prevalence of apoptotic cells were analyzed statistically using Student's *t*-test. A value of $P < 0.05$ was considered statistically significant.

Results

Ovarian Dynamics

Three cows showed 2 FWs in the estrous cycle (Fig. 1a.), in which the CL was clearly identified by means of ultrasonography on Day 1.7 ± 0.3 from estrus (Day 0). The CL reached its maximum size on Day 11 p.m. with a mean diameter 24.5 ± 2.4 mm. Plasma progesterone (P₄) increased concomitantly with the diameter of CL and reached its maximum level on Day 13 a.m. (5.3 ± 0.5 ng/ml). Emergence of FW 1 and FW 2 were observed on Day 1.3 ± 0.3 and 10.2 ± 0.3 , respectively, with mean diameters of DF 4.5 ± 1.5 mm and 5.4 ± 0.5 mm, respectively. The diameters of the SF in FW 1 and FW 2 at emergence were 4.9 ± 0.3 mm and 5.2 ± 0.9 mm, respectively. The DF of FW 1 reached a maximum diameter of 12.2 ± 0.8 mm on Day 7 p.m. and then regressed gradually. The SF of FW 1 increased its diameter until Day 4 a.m. (8.2 ± 1.0 mm) and then regressed. The DF of FW 2 developed until the day of ovariectomy with a mean diameter of 11.7 ± 0.8 mm. The SF of FW 2 increased its diameter until Day 13 a.m. (6.6 ± 0.3 mm) and then regressed gradually.

The other three cows had 3 FWs in the estrous cycle (Fig. 1b.). The CL was clearly identified on Day 1.2 ± 0.3 with a mean diameter of 12.9 ± 2.3 mm. The CL attained its maximum diameter on

Day 11 a.m. (22.9 ± 2.6 mm). Plasma P_4 increased concomitantly with an increase in CL diameter and reached its maximum level on Day 13 p.m. (5.5 ± 0.4 ng/ml). Emergence of FW 1, FW 2 and FW 3 was on Day 1.2 ± 0.3 (5.5 ± 1.1 mm), 8.8 ± 0.3 (6.1 ± 0.7 mm) and 14.8 ± 1.3 (4.7 ± 0.9 mm), respectively. The DF of FW 1 and FW 2 increased its diameter until Day 7 a.m. (12.6 ± 0.8 mm) and Day 15 p.m. (11.2 ± 1.3 mm), respectively, and then regressed gradually. The DF in FW 3 developed until the day of ovariectomy with a mean diameter of 9.4 ± 3.0 mm. The SF of the FW 1, 2 and 3 emerged on Day 1.3 ± 0.6 (5.5 ± 0.6 mm), 8.5 ± 1.3 (5.1 ± 0.6 mm) and 14.8 ± 1.8 (4.7 ± 1.3 mm) and increased its diameter until Day 3 p.m. (7.1 ± 0.4 mm), Day 11 p.m. (6.6 ± 0.5 mm) and Day 15 p.m. (6.5 ± 3.9 mm), respectively.

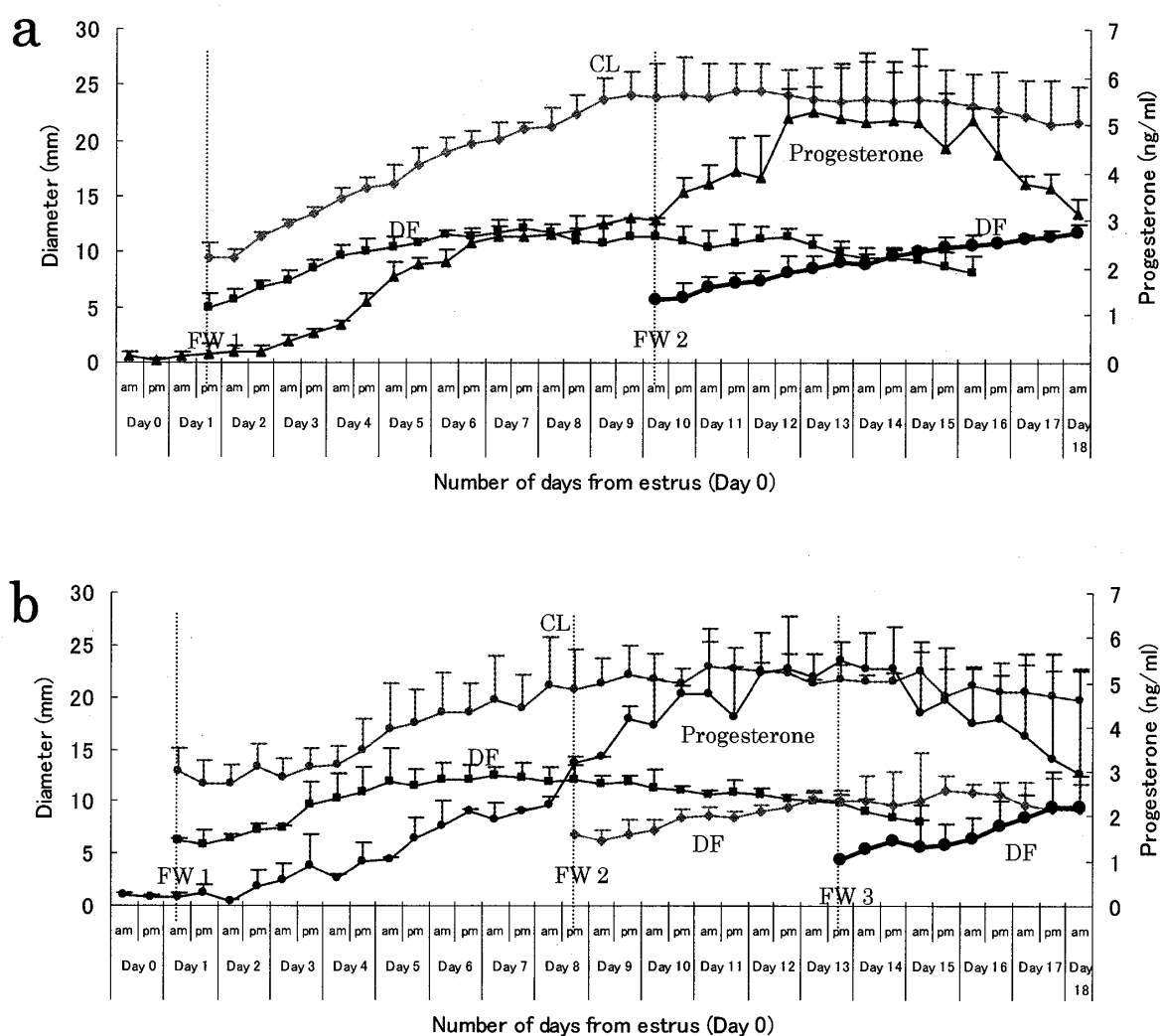


Figure 1. Ovarian dynamics and plasma P_4 levels in (a) cows with 2 FWs and (b) cows with 3 FWs. They were observed twice daily by means of transrectal ultrasonography until Day 18 a.m. of the estrous cycle. (CL = corpus luteum, DF = dominant follicle, FW = follicular wave).

Diameter of the CL on Day 18 a.m. was not different in cows with 2 FWs (21.7 ± 3.1 mm) and cows with 3 FWs (19.7 ± 3.0 mm), and there was no difference in P_4 levels between the two groups (3.1 ± 0.3 ng/ml and 3.0 ± 2.3 ng/ml, respectively). The preovulatory DF in cows with 2 FWs emerged 4 days earlier than in cows with 3 FWs, where the DF emerging on Day 10.2 ± 0.3 in cows with 2 FWs compared to Day 14.8 ± 1.3 in cows with 3 FWs ($P < 0.05$). Nevertheless, the diameter of